

Case Report

Epstein-Barr virus-associated hemophagocytic lymphohistiocytosis in a ten-year-old girl accompanied by posterior reversible encephalopathy syndrome and disseminated herpes simplex virus infection

Ryuta Itakura^{*}, Fumihiko Namba, Ayumu Arakawa,
Yoshitaka Asano, Koichi Moriwaki, Masanori Tamura

Department of Pediatrics, Saitama Medical Center, Saitama Medical University

Posterior reversible encephalopathy syndrome (PRES) has become a common disease entity. Clinically, the patient usually presents with acute onset of neurological problems including headache, convulsions and visual impairment or blindness. On the other hand, disseminated herpes simplex virus (HSV)-1 infection is usually observed in immunocompromised individuals. We present a case of cyclosporin A (CyA)-induced PRES and disseminated HSV-1 infection during chemotherapy treatment with etoposide, prednisolone and CyA for Epstein-Barr virus-associated hemophagocytic lymphohistiocytosis (EBV-HLH). The combination therapy for EBV-HLH was initially effective. However, the patient developed prominent side effects, drug-induced encephalopathy and the risk of infection under an immunosuppressive state. She showed an excellent outcome after discontinuation of CyA and treatment with acyclovir and methylprednisolone. In conclusion, this case report emphasizes the difficulty in choosing an appropriate treatment for EBV-HLH when some side effects develop and the importance of making a timely diagnosis for preventing progression to permanent damage from HLH-associated encephalopathy or PRES.

J Saitama Medical University 2015; 41(2): 139-143

(Received August 7, 2014 / Accepted November 28, 2014)

Keywords: Epstein-Barr virus, hemophagocytic lymphohistiocytosis, cyclophosphamide, posterior reversible encephalopathy syndrome, herpes simplex virus-1

Introduction

Posterior reversible encephalopathy syndrome (PRES) has become a common disease entity. Clinically, the patient usually presents with acute onset of neurological problems including headache, convulsions and visual impairment or blindness. The disease may be reversed by initiation of an appropriate treatment; therefore, it is important to make a timely diagnosis to prevent progression to permanent damage. Disseminated herpes simplex

virus (HSV)-1 infection is rare and can predominantly be seen in immunocompromised individuals like neonates, patients with hemato-oncologic malignancies, transplant recipients, or due to immunosuppressive medication. Despite use of advanced diagnostic methods and antiviral therapy, this disease continues to have high morbidity and mortality. We present a case of Epstein Barr virus-associated hemophagocytic lymphohistiocytosis (EBV-HLH) accompanied by cyclosporin A (CyA)-induced PRES and disseminated HSV-1 infection.

Case Report

A 10-year-old girl with no family history of HLH was admitted to the Pediatrics inpatient unit of our hospital

^{*} Author :Department of Pediatrics, Saitama Medical Center, Saitama Medical University

1981, Kamoda, Kawagoe, Saitama 350-8550, Japan

○ The authors declare that there are no conflicts of interest associated with the present study.

with continuous fever and swollen cervical lymph nodes. She was transferred from a primary care center because her fever could not be controlled even after administration of oral antibiotics for 3 days. Besides asthma, which was well controlled, the patient had no other known medical problems or family history of specific diseases.

On admission, she was conscious but not physically active. An oral cavity examination revealed a congested and red pharynx with white patches on her tonsils. Her skin, abdominal and genital findings were normal. A maximum temperature of 40.2 °C was recorded per axilla. Her heart rate was 130 beats/min and her SpO₂ was 96% on room air. She had bilateral swollen lymph nodes (1.5 cm) in the neck region, with tenderness. Her total WBC count was 10,500 cells/mm³, and she tested negative for group A streptococci, adenoviruses and cytomegalovirus. Her serum was positive for EBV viral capsid antigen immunoglobulin M (IgM) (>1.0) and negative for EBV nuclear antigen (<0.5). A presumptive diagnosis of acute infectious mononucleosis was made and a wait-and-see approach was adopted (Fig. 1). Because the platelet counts decreased to 90,000 cells/mm³, bone marrow aspiration

was performed on the day 4, which demonstrated hemophagocytosis by macrophages (Fig. 2). The patient met the diagnostic criteria for HLH. The EBV DNA load in peripheral blood mononuclear cells (PBMCs) was 9.4×10^4 copies/10⁶ cells, and her serum ferritin levels increased to 1,302 ng/ml on the day 4. After the diagnosis of EBV-HLH, a combination therapy with prednisolone (PSL) at 2 mg/kg/day and CyA at 3 mg/kg/day was initiated. Etoposide (VP-16) at 150 mg/m² twice a week was added on the day 15 because the PSL/CyA therapy was not effective. On the day 19, a generalized vesicular eruption developed and the administration of acyclovir (ACV) 30 mg/kg/day was initiated (Fig. 1). Subsequently, the patient was diagnosed with disseminated HSV infection and herpetic keratoconjunctivitis by the detection of HSV in the serum using PCR (4.0×10^6 copies/10⁶ cells), and VP-16 was discontinued because of its bone marrow depressant effects.

On the day 29, the patient developed seizures and was administered diazepam followed by phenobarbital. Serum sodium, potassium, and calcium levels were 133 mEq/L, 3.6 mEq/L, and 8.5 mg/dL, respectively. Serum CyA level in continuous intravenous infusion

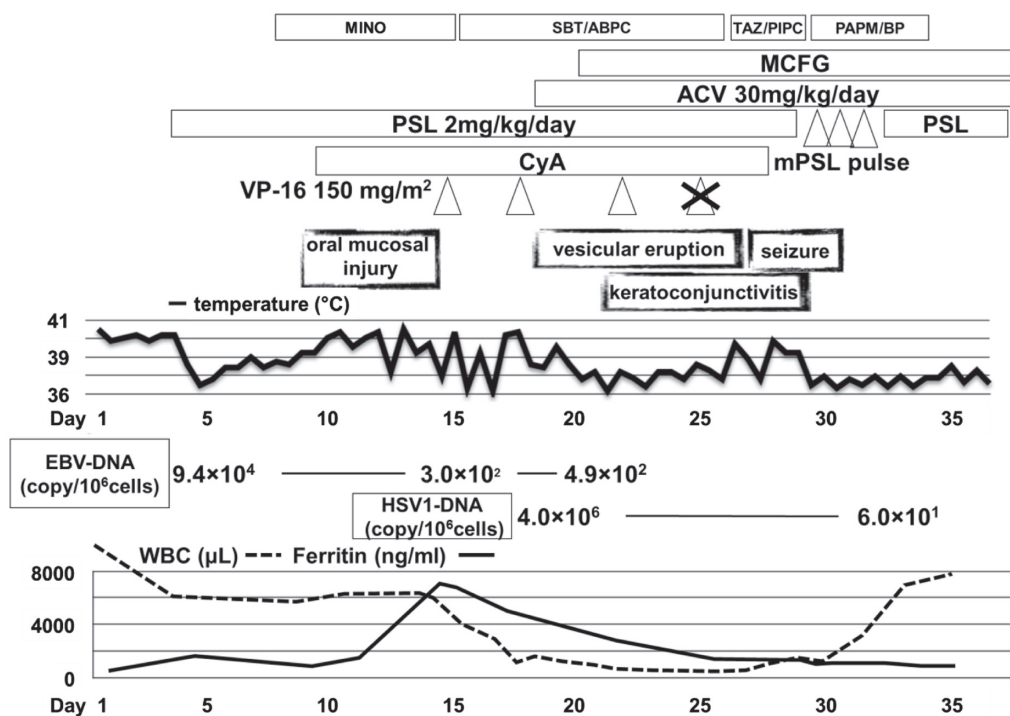


Fig. 1. Scheme of clinical course in this case. ACV, acyclovir; CyA, cyclosporine A; MCFG, micafungin; MINO, minocycline; mPSL, methylprednisolone; PAPM/BP, panipenem/betamipron; PSL, prednisolone; SBT/ABPC, sulbactam/ampicillin; TAZ/PIPC, tazobactam/piperacillin; VP-16, etoposide.

was 101.6 ng/mL. Her blood pressure was elevated to 168/118 mmHg. A presumptive diagnosis of PRES induced by CyA, central nervous system symptoms of EBV-HLH or herpes simplex encephalitis was made. Consequently, CyA was discontinued, whereas ACV was continued. In addition, methylprednisolone (mPSL) pulse therapy was initiated. Brain MRI showed a high intensity signal on T2WI, DWI, and ADC-map in the subcortical white matter and cortex within the right parietal, temporal and occipital lobes (Fig. 3a, 3b, and 3c, respectively). No mass, hemorrhage or hydrocephalus was noted. The cerebrospinal fluid (CSF) was clear and <1 WBC/mm³; CSF was also negative for HSV DNA ($<1.0 \times 10^2$ copies/ 10^6 cells). An EEG showed no slow wave or epileptic discharge, indicating no evidence of encephalitis or encephalopathy. The antiseizure medications were titrated down over the next 2 weeks. On the day 43, the high intensity signal on T2WI disappeared (Fig. 3d). A provisional diagnosis of PRES was made. Exacerbation of EBV-HLH after the discontinuation of CyA was not observed. After a long

stay in the hospital, the patient returned to her normal status.

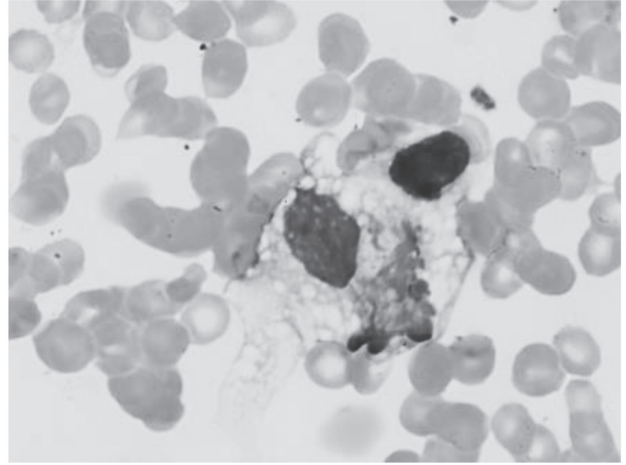


Fig. 2. Day 4 bone marrow examination showing a reduction of the cellularity in all lineages. Macrophages were increased with signs of hemophagocytosis.

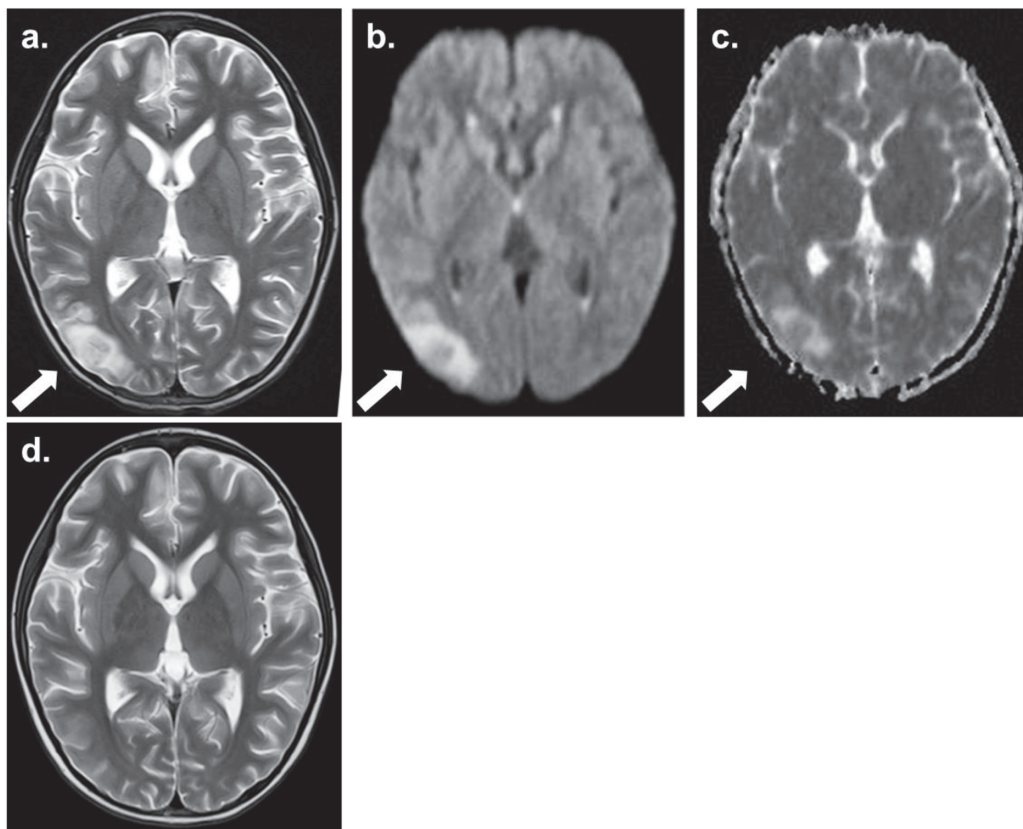


Fig. 3. a-c) Day 29 MRI of brain showing a high intensity signal on T2WI (a), DWI (b), and ADC-map (c) in the subcortical white matter and cortex within the right parietal, temporal and occipital lobes (white arrow). d) Day 43 MRI of brain showing no high intensity signal on T2WI.

Discussion

HLH is a potentially fatal condition because of dysregulated lymphocyte activation and proliferation that is mainly characterized by impaired or inactive NK and cytotoxic T cells, leading to macrophage hyperactivation and cytokine overexpression¹⁾. HLH is frequently fatal if not treated promptly. HLH treatment is based on the control of the cytokine storm and cellular proliferation. In particular, immunochemotherapy, as proposed by the Histiocyte Society, consists of a combination therapy with VP-16, dexamethasone and CyA²⁾. The prompt use of VP-16 greatly improves the outcome³⁾ and the use of CyA has been reported to reduce the rate of fatal infections associated with neutropenia⁴⁾.

We have reported a case of EBV-HLH that was treated with a combination of VP-16, PSL and CyA. This combination therapy was effective. Disease progression, such as prolonged fever and abnormal laboratory values, was well controlled. However, the patient suffered complications caused by disseminated HSV-1 infection, herpetic keratoconjunctivitis and PRES. On reviewing the literature, we found that although these immunomodulating chemotherapies are effective, they are also commonly associated with side effects. Most side effects worsen following a prolonged course of treatment⁵⁾. Specifically, CyA is associated with severe headache, hypertension, seizures and renal impairment. PSL has many well-described adverse effects, including hyperglycemia, fluid retention, hypertension and weight gain. VP-16 is associated with myelosuppression and development of secondary leukemia. Therefore, a combination therapy with VP-16, PSL and CyA for HLH should be carefully performed while monitoring the side effects, particularly the risk of developing disseminated infection under long-term immunosuppression and drug-induced encephalopathy.

PRES is a transient clinico-radiologic phenomenon characterized by seizures, headache, altered mental status and visual impairment with abnormal signal lesions on MRI. Since it was first proposed in 1996 by Hinchey, et al.⁶⁾, PRES has been reported in various conditions and has developed in association with the use of medications such as chemotherapeutic agents, immunosuppressive drugs, immunoglobulins and antiangiogenic drugs⁷⁻⁹⁾. Significant neurological toxicity, which is proposed to be PRES, has been reported during treatment with the HLH-2004 protocol

from the Histiocyte Society¹⁰⁾. Because HLH is a rare multisystem disorder in which the occurrence of PRES is even rarer, it can be difficult to distinguish PRES from other neurological manifestations such as central nervous system symptoms of EBV-HLH or herpes simplex encephalitis. Lee and colleagues compared the clinical and laboratory findings at the development of PRES between HLH patients with and without PRES to determine the putative risk factors. Among the several factors, preceding hypertension, a preceding rise in ferritin level >50% compared with 1 week before development of PRES, and hyponatremia (<135 mEq/L) were statistically significant, indicating that these factors apparently comprise putative risk factors for PRES complicated during induction chemotherapy¹⁰⁾. The present case did not show any risk factors for PRES at the development of seizures except mild hyponatremia (serum sodium: 133 mEq/L). In the present case, it was difficult to choose an appropriate treatment for EBV-HLH accompanied by PRES and HSV-1 infection, because of the following reasons: (1) treatment for PRES, which involves discontinuation of CyA, is opposite to the treatment for EBV-HLH itself and (2) diagnosis of herpes simplex encephalitis requires isolation and identification of HSV-1 DNA from CSF by PCR, which takes a few days. However, careful differential diagnosis of these neurologically toxic conditions from other causes of neurological conditions was done and permanent damage to the affected brain tissues was eventually prevented. mPSL pulse therapy was alternatively given instead of CyA to prevent exacerbations of HLH and used in the treatment of acute viral encephalitis because the diagnosis of herpes simplex encephalitis had not yet been excluded at that time.

In summary, we report a case of PRES and disseminated HSV-1 infection during multi-agent chemotherapy for EBV-HLH. Our case highlights the need for physicians to pay adequate attention to the side effects of combination chemotherapies for HLH and to make a timely diagnosis to prevent progression to permanent damage from HLH-associated encephalopathy or PRES.

Acknowledgements

The authors are grateful to Dr. Katsuyoshi Koh and his colleagues from Saitama Children's Hospital for their useful advice and suggestions on treating the patient.

References

- 1) Maakaroun NR, Moanna A, Jacob JT, Albrecht H. Viral infections associated with haemophagocytic syndrome. *Rev Med Virol* 2010;20:93-105.
- 2) Henter JI, Aricò M, Egeler RM, Elinder G, Favara BE, Filipovich AH, et al. HLH-94: a treatment protocol for hemophagocytic lymphohistiocytosis. HLH study Group of the Histiocyte Society. *Med Pediatr Oncol* 1997;28:342-7.
- 3) Imashuku S, Kuriyama K, Teramura T, Ishii E, Kinugawa N, Kato M, et al. Requirement for etoposide in the treatment of Epstein-Barr virus-associated hemophagocytic lymphohistiocytosis. *J Clin Oncol* 2001;19:2665-73.
- 4) Oyama Y, Amano T, Hirakawa S, Hironaka K, Suzuki S, Ota Z. Haemophagocytic syndrome treated with cyclosporin A: a T cell disorder? *Br J Haematol* 1989;73:276-8.
- 5) Imashuku S, Teramura T, Tauchi H, Ishida Y, Otoh Y, Sawada M, et al. Longitudinal follow-up of patients with Epstein-Barr virus-associated hemophagocytic lymphohistiocytosis. *Haematologica* 2004;89:183-8.
- 6) Hinchey J, Chaves C, Appignani B, Breen J, Pao L, Wang A, et al. A reversible posterior leukoencephalopathy syndrome. *N Engl J Med* 1996;334:494-500.
- 7) Saeed B, Abou-Zor N, Amer Z, Kanani I, Hilal M. Cyclosporin-A induced posterior reversible encephalopathy syndrome. *Saudi J Kidney Dis Transpl* 2008;19:439-42.
- 8) Yokobori S, Yokota H, Yamamoto Y. Pediatric posterior reversible leukoencephalopathy syndrome and NSAID-induced acute tubular interstitial nephritis. *Pediatr Neurol* 2006;34:245-7.
- 9) Hourani R, Abboud M, Hourani M, Khalifeh H, Muwakkit S. L-asparaginase-induced posterior reversible encephalopathy syndrome during acute lymphoblastic leukemia treatment in children. *Neuropediatrics* 2008;39:46-50.
- 10) Lee G, Lee SE, Ryu KH, Yoo ES. Posterior reversible encephalopathy syndrome in pediatric patients undergoing treatment for hemophagocytic lymphohistiocytosis: clinical outcomes and putative risk factors. *Blood Res* 2013;48:258-65.

可逆性後頭葉白質脳症と播種性ヘルペス感染症を合併したEBウイルス関連血球貪食症候群の1例 板倉隆太, 難波文彦, 荒川歩, 浅野祥孝, 森脇浩一, 田村正徳

可逆性後頭葉白質脳症は通常臨床的には頭痛・痙攣・視覚障害等の神経症状で発症するしばしば認める疾患である。一方、播種性ヘルペス感染症は免疫不全患者で認める感染症である。今回我々は、EBウイルス関連血球貪食症候群に対するエトポシド・プレドニゾロン・シクロスポリンを用いた多剤併用化学療法中に、シクロスポリン関連可逆性後頭葉白質脳症と播種性ヘルペス感染症と診断された10歳女児を経験したので報告する。EBウイルス関連血球貪食症候群に対する併用療法は当初有効であったが、薬剤関連脳症と免疫抑制下での全身性感染症発症という重篤な合併症を認めた。シクロスポリン中止とアシクロビル・メチルプレドニゾロン投与により速やかな症状の回復を認めた。以上、本症例により、①有害事象が生じた際のEBウイルス関連血球貪食症候群に対する適切な治療法選択の難しさと、②血球貪食症候群関連脳症または可逆性後頭葉白質脳症による後遺症を回避するために早期診断が重要と考えられた。